

1-21-1963

The value of visual fields in the diagnosis of focal and oral infections

Charles F. Raab
Pacific University

Paul L. Washburn
Pacific University

Recommended Citation

Raab, Charles F. and Washburn, Paul L., "The value of visual fields in the diagnosis of focal and oral infections" (1963). *College of Optometry*. 243.
<https://commons.pacificu.edu/opt/243>

This Thesis is brought to you for free and open access by the Theses, Dissertations and Capstone Projects at CommonKnowledge. It has been accepted for inclusion in College of Optometry by an authorized administrator of CommonKnowledge. For more information, please contact CommonKnowledge@pacificu.edu.

The value of visual fields in the diagnosis of focal and oral infections

Abstract

The value of visual fields in the diagnosis of focal and oral infections

Degree Type

Thesis

Rights

Terms of use for work posted in CommonKnowledge.

Copyright and terms of use

If you have downloaded this document directly from the web or from CommonKnowledge, see the “Rights” section on the previous page for the terms of use.

If you have received this document through an interlibrary loan/document delivery service, the following terms of use apply:

Copyright in this work is held by the author(s). You may download or print any portion of this document for personal use only, or for any use that is allowed by fair use (Title 17, §107 U.S.C.). Except for personal or fair use, you or your borrowing library may not reproduce, remix, republish, post, transmit, or distribute this document, or any portion thereof, without the permission of the copyright owner. [Note: If this document is licensed under a Creative Commons license (see “Rights” on the previous page) which allows broader usage rights, your use is governed by the terms of that license.]

Inquiries regarding further use of these materials should be addressed to: CommonKnowledge Rights, Pacific University Library, 2043 College Way, Forest Grove, OR 97116, (503) 352-7209. Email inquiries may be directed to: copyright@pacificu.edu

THE VALUE OF VISUAL FIELDS IN THE DIAGNOSIS OF FOCAL AND ORAL INFECTIONS

CLINICAL YEAR THESIS

Jan. 21, 1963

By

Charles F. Raab

Paul L. Washburn

INDEX

PURPOSE	1
PROCEDURE	2
ORGANIZATION OF DATA	3
CASE STUDIES	4
CONCLUSION	20

ACKNOWLEDGEMENTS

Our gratitude is extended to Dr. Detleff T. Jans, Professor of Visual Fields, Pacific University College of Optometry, under whose direction this research was conducted.

We would also like to acknowledge with appreciation the efforts of the dentists whose help and advice made this research project possible, viz: Dr. Robert K. Erickson, Dr. Howard C. Glesmann, and Dr. Robert H. Schmunk of Hillsboro, Oregon, and Dr. Joseph R. Gibson of Forest Grove, Oregon.

Our appreciation also goes to Dr. P. L. Meacham, oral surgeon, of Portland, Oregon, and Dr. Raymond R. Roy, Optometrist, Portland, Oregon, for their help and encouragement in this research.

C. F. Raab

P. L. Washburn

INTRODUCTION

As a part of an analytical examination on February 15, 1962, the right eye of Mrs. D. R. was routinely examined with a red-green bichrome chart and the patient elicited a subjective response in accord with the expected. Upon presentation of the same red-green chart to the left eye, however, it was found that the patient reported seeing the colors red and white, and was unable to see the color green.

A thorough ophthalmoscopic examination revealed no apparent pathology, but it was maintained that a response of this nature was not in accord with an expected variation from the norm, and this patient was referred for full mouth x-rays. The dental report showed three infected, impacted molars and one infected residual root; all of which were estimated to have been present for many years, and none of which offered any feeling of discomfort.

Subsequent visual fields, taken before the patient underwent oral surgery, indicated an enlargement of the physiological blind spot of both eyes for the colors red and blue. The left eye showed a paracentral scotoma for white, and for the colors red and blue.

At that time, with only one clinical case in hand, it was not possible to infer that the visual defects were resultant of the oral pathology.

The above findings were presented to several practicing dentists for their opinion of, and clinical experience with this problem.

At the conclusion of these presentations, it was found that some dentists were able to recall patients from their practice, who were aware of relief from visual discomfort subsequent to oral surgery.

It was then felt that there was a high probability on both an anatomical and clinical level, that at least some focal infections did affect the eye.

With this thought in mind, a procedure was established, whereby the dentists could refer patients, with known oral infections, to the optometric clinic for testing. Routine visual fields were also taken on the authors patients, and suspects were referred to the dentists for full mouth x-rays.

PURPOSE

This project was undertaken in an effort to establish a diagnostic technique whereby the optometrist, through routine testing, may recognize and refer patients who are hosting oral infections which may have a pathological affect on the eye.

It should be realized that the patients most likely to be affected by prolonged, chronic, oral infections are those who have no subjective symptoms of pain or discomfort. This category may include: apical and periapical abscesses; impacted, infected teeth; and septic residual roots, the latter of which may be found in denture wearers who have undergone full mouth extractions, but have retained broken roots.

This research program will offer a series of case studies in an effort to emphasize the value of visual field examinations, and to present some of the more characteristic visual fields found in this research, and known to be resultant of oral infections.

PROCEDURE

All patients who habitually wore glasses were examined with their prescription in place.

An ophthalmoscopic examination was recorded for each patient as an alert to congenital or pathological anomalies which could be expected to affect the findings.

The instrument of choice was the A. O. Lloyd Stereocampimeter, and all examinations were conducted under the self contained seven foot candles of illumination provided by the instrument.

The isopters of the peripheral fields were plotted by moving a $\frac{1}{2}$ mm white, round, test object from the edge of the fields chart toward the central point of fixation until the patient reported first recognition of this object. This peripheral form field will be represented by a solid white line.

The central twenty degrees of vision was examined for scotomas with $\frac{1}{2}$ mm white, blue, and red test objects.

All scotomas, including the physiological blind spot, were plotted by using the invisible to visible technique at first recognition. These scotomas will be recorded in accordance with the Zuckermann Code of _____ for white, with the physiological blind spots being cross checked; -.-.-. for the color blue, and - - - - for the color red.* All absolute scotomas will be solid white filled, and all color scotomas will be outlined by their respective color code.

* Zuckermann, J., Perimetry, Philadelphia, Lippincott Co., 1954, pg 95.

ORGANIZATION OF DATA

The following data was gathered from a total of twenty six subjects; thirteen males and thirteen females. The ages ranged from thirteen to seventy-eight years in the female group, and from twenty to sixty-two years in the male group.

Twelve of these subjects formed a control group who had recently received dental care and were known to be in good dental health. The visual fields of these twelve control subjects were found to fall within the expected variation of normalcy.

Of the fourteen subjects in the test group, seven subjects were referred from the clinic for full mouth x-rays on the basis of visual field defects and seven were referred into the clinic for visual field examinations on the basis of dental x-rays which indicated oral pathology.

Of the seven patients referred out of the clinic for full mouth x-rays, five were found to need dental surgery, one was found to have chronic tonsillitis and one was negative.

Of the seven patients referred into the clinic on the basis of x-ray diagnosis, six were shown to have visual field defects and one, who was suffering from an acute pericoronitis of only one weeks duration, showed a negative visual field.

CASE STUDIES

The forthcoming case studies are considered to be representative of the total test group in that they exhibit typical visual field defects found to be diagnostic of oral pathology.

Each of these case studies will include data provided by the dental or medical, and optometric examinations.

The dental or medical case analysis will include; the patient's chief complaint and diagnosis thereof, extent of involvement, and estimated duration of infection. X-rays will accompany the case studies involving oral pathology. The optometric case studies will include; the patient's habitual visual acuity, an ophthalmoscopic examination, the patient's chief complaint, and the visual fields.

PATIENT: Mrs. T. D., age 25.

DENTAL EXAMINATION:

CHIEF COMPLAINT: Pain and sensitivity in the affected area.

DIAGNOSIS: Pulpal death resulting in a periapical breakdown and abscess formation of the upper right lateral incisor.

EXTENT OF INVOLVEMENT: 6 mm periapical rarefaction.



ESTIMATED DURATION OF INFECTION: Three years or more.

OPTOMETRIC EXAMINATION:

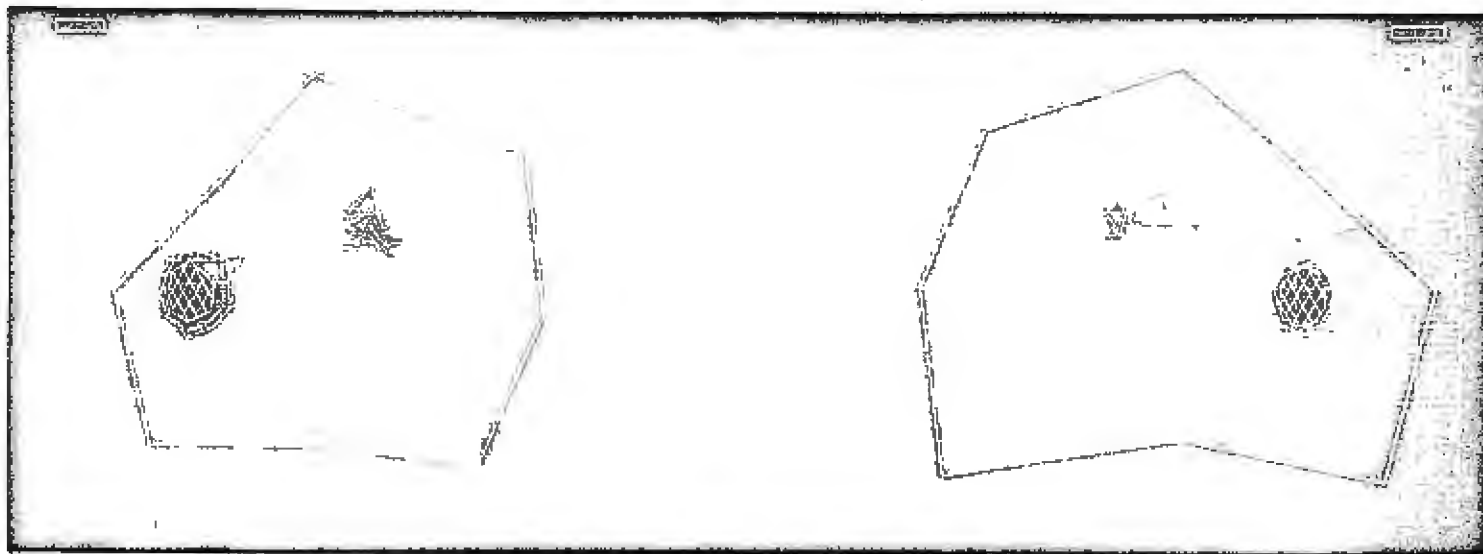
VISION: R. E. 20/15 L. E. 20/15 Unaided acuity.

OPHTHALMOSCOPY: Both eyes were found to be normal.

CHIEF COMPLAINT: No subjective visual symptoms.

VISUAL FIELDS: As shown below.

VISUAL FIELDS BEFORE DENTAL THERAPY

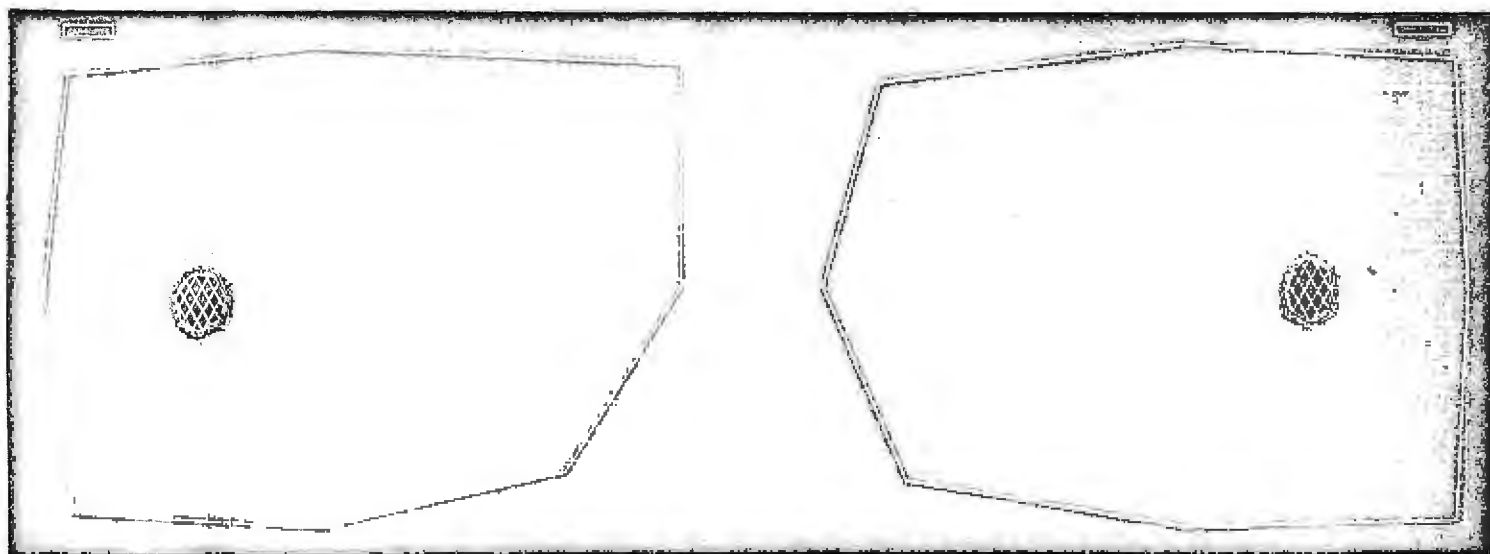


DATE: April 6, 1962

TIME: 4:00 P.M.

OBSERVATION: There is an irregular restriction of the peripheral white field; an enlargement of the physiological blind spots for the colors red and blue, and a scotoma for red and blue in the superior nasal quadrant of both fields.

VISUAL FIELDS 253 DAYS AFTER DENTAL THERAPY



DATE: December 15, 1962

TIME: 4:30 P.M.

OBSERVATION: The visual fields are found to be normal in both eyes.

PATIENT: Miss J. H., age 19.

MEDICAL EXAMINATION:

CHIEF COMPLAINT: None, the dental x-rays were negative and hence the patient was referred to her family physician for a complete physical examination.

DIAGNOSIS: Chronic tonsillitis and lymphadenitis.

EXTENT OF INVOLVEMENT: Restricted to the tonsils and surrounding lymph glands.

ESTIMATED DURATION OF INFECTION: Intermittent occurrence for three years.

OPTOMETRIC EXAMINATION:


VISION: R. E. 20/20 L. E. 20/20 Unaided acuity.

OPHTHALMOSCOPY: Both eyes were found to be normal.

CHIEF COMPLAINT: Miss J. H. reported a dull pain in back of her eyes upon saccadic fixations, monocular diplopia while viewing a red target on the stereocampimeter, extensive photophobia, and extreme headaches accompanied by general nausea and vertigo. The headaches were located in and around both orbits and the forehead, found upon arising and aspirin did not provide relief. She also stated that there was extensive lacrimation and frequently a white halo or mist located around windows.

VISUAL FIELDS: As shown below.

VISUAL FIELDS BEFORE MEDICAL THERAPY

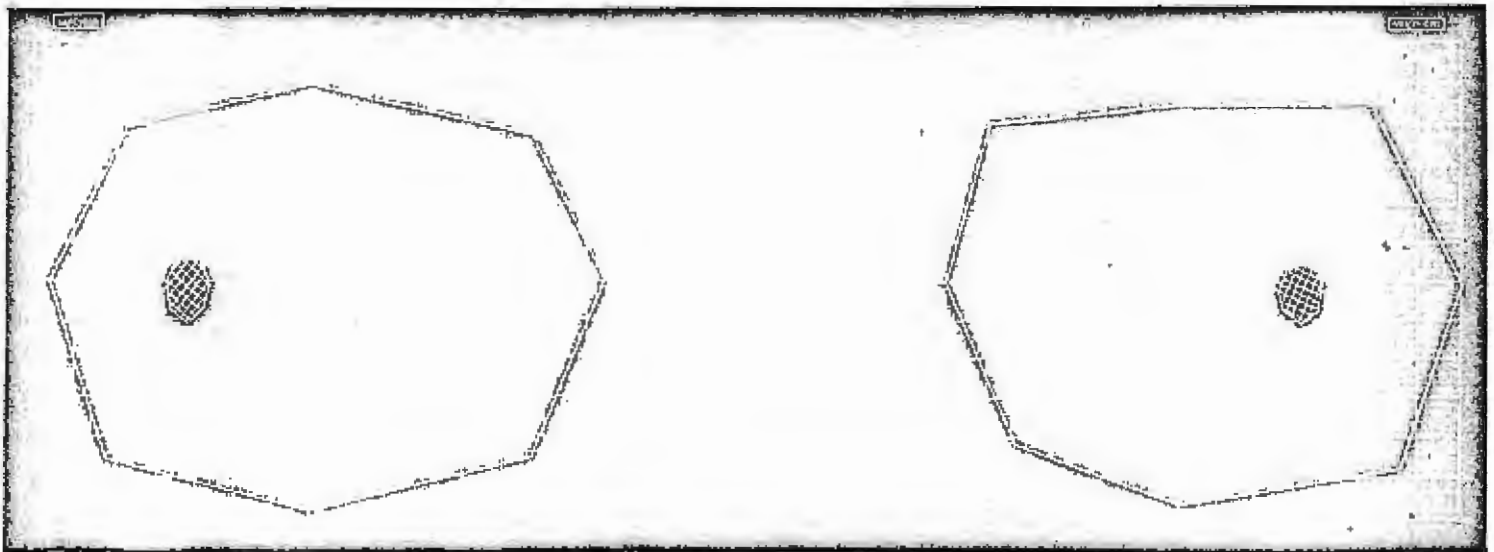


DATE: April 5, 1962.

TIME: 4:00 P.M.

OBSERVATION: There is an irregular restriction for both peripheral white fields, and an irregular bilateral enlargement for the physiological blind spots. The left eye shows a temporocentral scotoma for the color blue. The colors red and blue were not used for the physiological blind spot.

VISUAL FIELDS 254 DAYS AFTER MEDICAL THERAPY



DATE: December 15, 1962

TIME: 2:30 P.M.

OBSERVATION: The visual fields are found to be normal in both eyes.

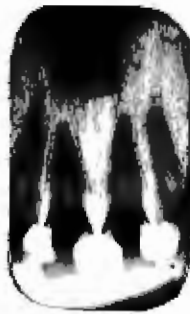PATIENT: Mrs. A. H., age 35.

DENTAL EXAMINATION:

CHIEF COMPLAINT: Pain and discomfort around the area of involvement.

DIAGNOSIS: Acute periapical abscess of the upper left central incisor.

EXTENT OF INVOLVEMENT: Upper left central incisor only.



ESTIMATED DURATION OF INFECTION: Approximately six months.

OPTOMETRIC EXAMINATION:

VISION: R. E. 20/20 L. E. 20/40-1 Through habitual prescription.

OPHTHALMOSCOPY: Both eyes were found to be normal.

CHIEF COMPLAINT: Mrs. A. H. reported headaches of such magnitude that she required from two to six aspirin daily, and was forced to spend at least one day a week in bed.

Preliminary examination showed a hyperphoria, and the Raymond R. Roy technique of prolonged occlusion was employed following dental surgery. The prescription written from this testing procedure was:

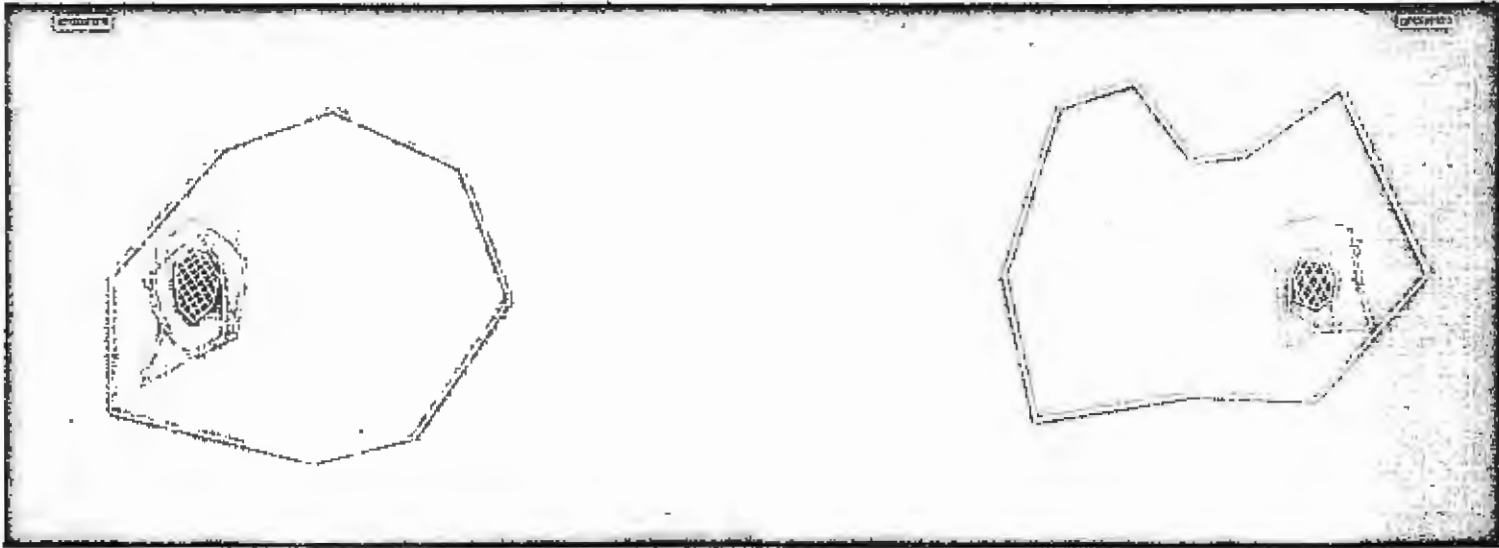
R.E. +1.75-2.00 X 5 \odot 4BI \odot 3BD Acuity 20/20

L.E. +3.50-4.00 X 2 \odot 4BI \odot 3BH Acuity 20/20-1

With this prescription the patient is free from headaches and is enjoying a more productive life.

VISUAL FIELDS: As shown below.

VISUAL FIELDS BEFORE DENTAL THERAPY

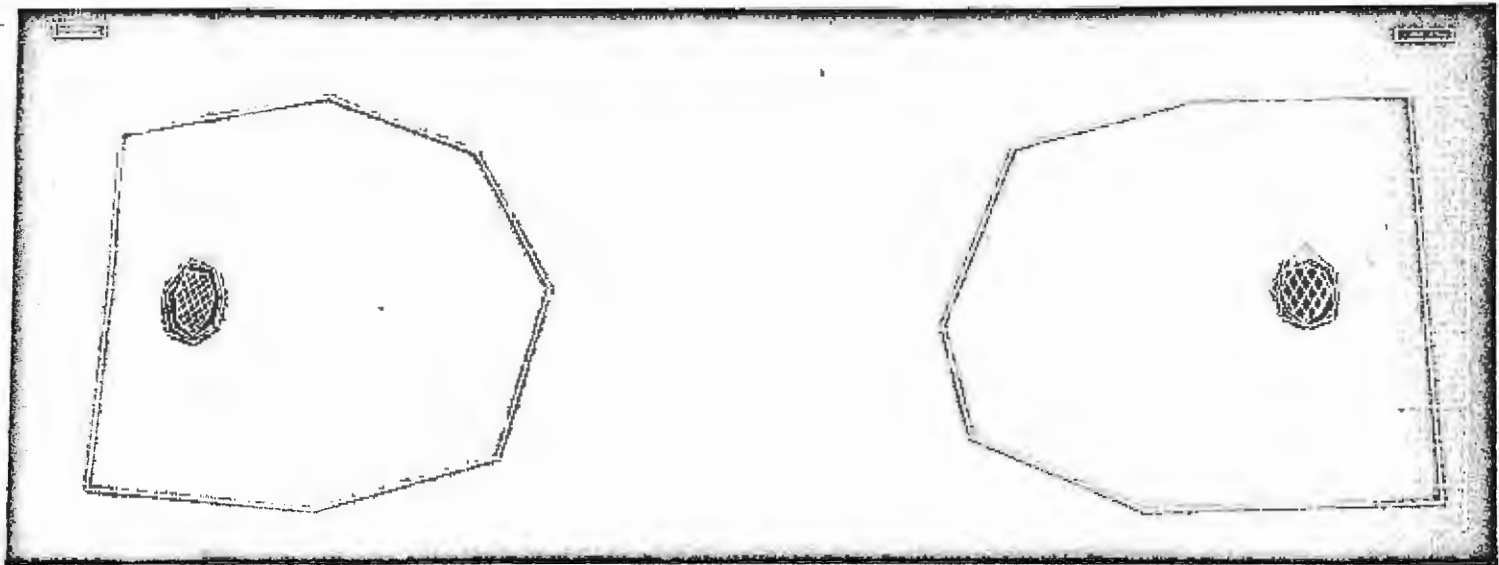


DATE: March 29, 1962.

TIME: 4:30 P.M.

OBSERVATION: There are irregular restrictions of the right peripheral field, and a general contraction of the left peripheral field. Both physiological blind spots show a marked enlargement for the colors of red and blue, and the left physiological blind spot shows an interlacing of these colors.

VISUAL FIELDS 35 DAYS AFTER DENTAL THERAPY

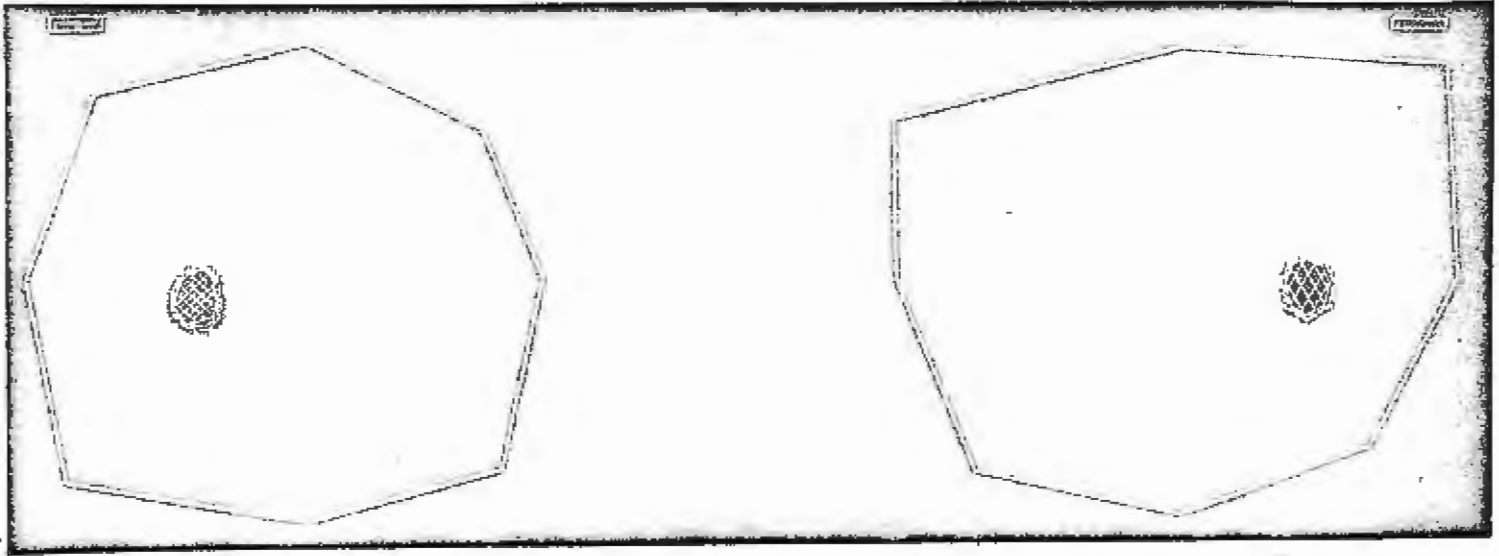


DATE: May 3, 1962

TIME: 2:15 P.M.

OBSERVATION: The peripheral fields are approaching normal, but the physiological blind spots continue to show an enlargement for the colors of red and blue.

VISUAL FIELDS 228 DAYS AFTER DENTAL THERAPY



DATE: November 12, 1962

TIME: 2:00 P.M.

OBSERVATION: The visual fields are found to be normal in both eyes.

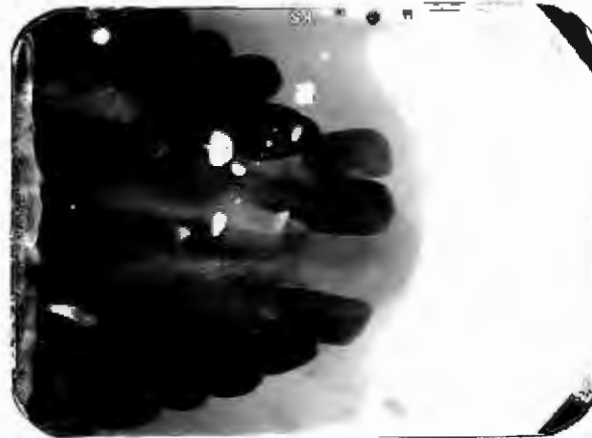
PATIENT: Miss D. L., age 13.

DENTAL EXAMINATION:

CHIEF COMPLAINT: None, the patient came in for a routine dental examination.

DIAGNOSIS: Radiolucent area involving the apical area of the upper right central and lateral incisors with complete atrophy of the lateral incisor root.

EXTENT OF INVOLVEMENT: Apex of the upper right lateral and central incisors. $8\frac{1}{2}$ mm by 12 mm.



ESTIMATED DURATION OF INFECTION: Undetermined, but could not logically have been observed before age 6 or 8.

OPTOMETRIC EXAMINATION:

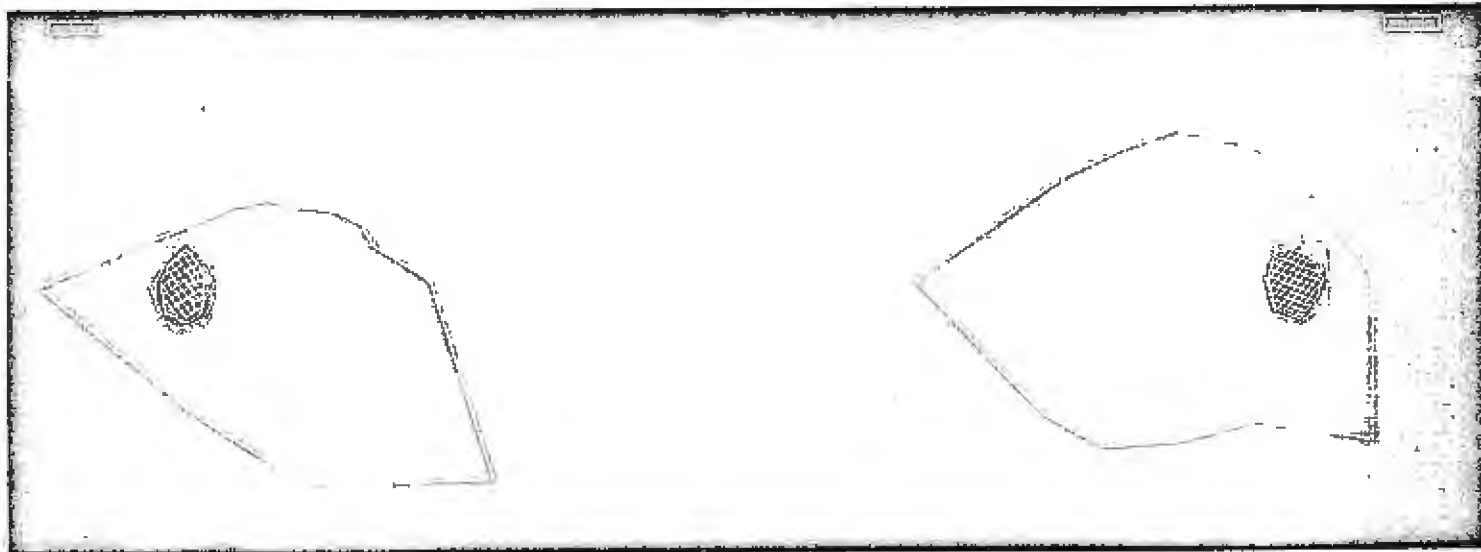
VISION: R. E. 20/15 L. E. 20/20-1.

OPHTHALMOSCOPY: Both eyes were found to be normal.

CHIEF COMPLAINT: No subjective symptoms.

VISUAL FIELDS: As shown below.

VISUAL FIELDS BEFORE DENTAL THERAPY

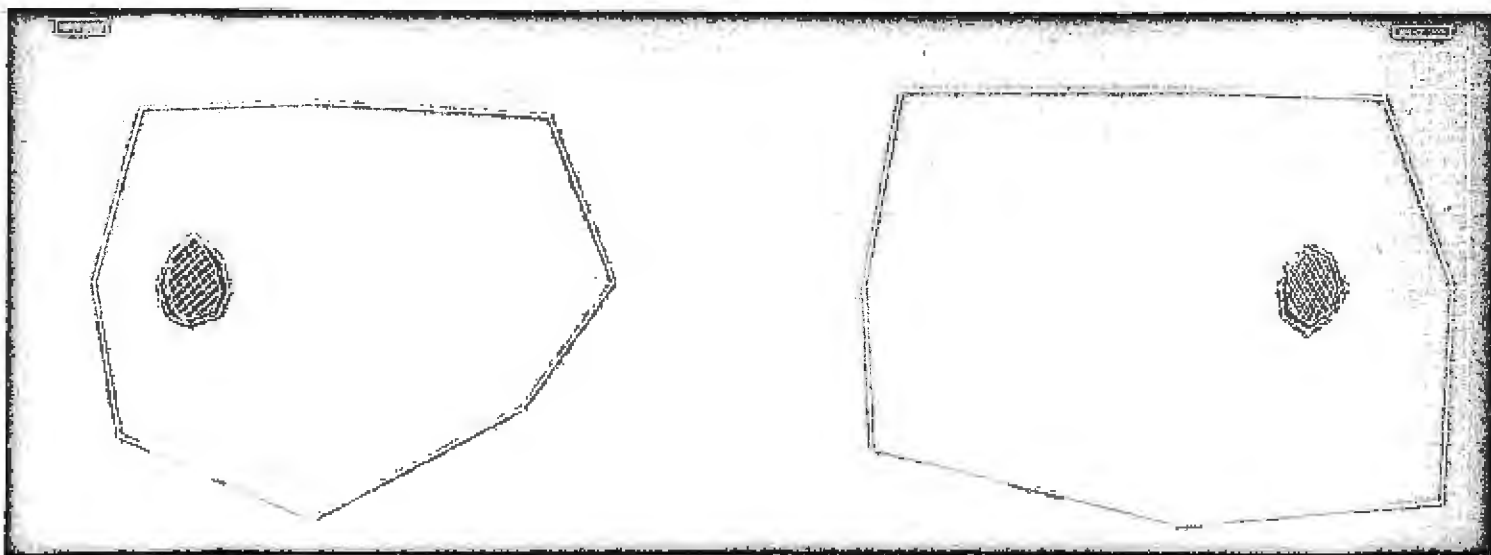


DATE: May 22, 1962

TIME: 10:30 A.M.

OBSERVATION: There is an irregular restriction of both peripheral white fields, and an irregular enlargement for the colors blue and red of the right physiological blind spot. The left eye shows an inferior paracentral scotoma for the color red.

VISUAL FIELDS 106 DAYS AFTER DENTAL THERAPY



DATE: September 5, 1962.

TIME: 9:30 A.M.

OBSERVATION: The visual field is found to be normal for the right eye, and is approaching normal for the left eye.


PATIENT: Mr. W. P., age 25.

DENTAL EXAMINATION:

CHIEF COMPLAINT: The patient noticed drainage at the site of the involvement in January of 1962, but did not come in for dental attention until May of 1962. There was no pain or discomfort, and the infection was discovered with dental x-rays.

DIAGNOSIS: Chronic periapical abscess.

EXTENT OF INVOLVEMENT: The apical one-third of both upper left bicuspids, with drainage established over the root area of the upper left first bicuspid.



ESTIMATED DURATION OF INFECTION: At least five months.

OPTOMETRIC EXAMINATION:

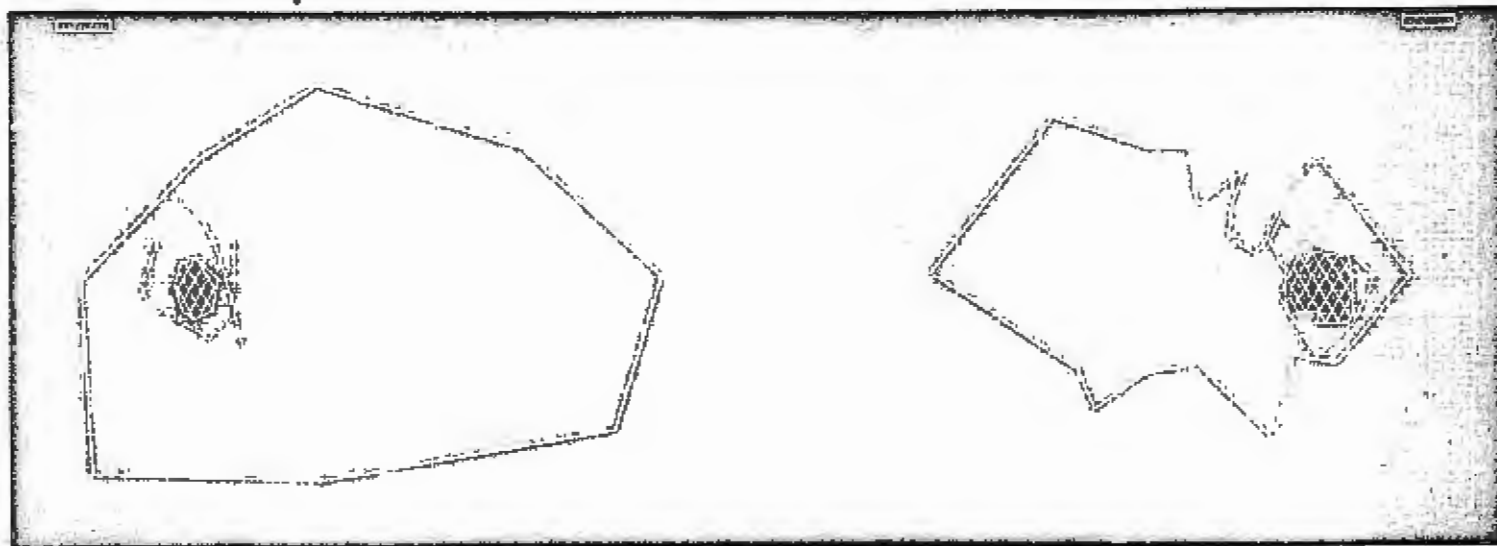
VISION: R. E. 20/25 L. E. 20/25 Through habitual prescription.

OPHTHALMOSCOPY: Both eyes were found to be normal.

CHIEF COMPLAINT: None.

VISUAL FIELDS: As shown below.

VISUAL FIELDS BEFORE DENTAL THERAPY

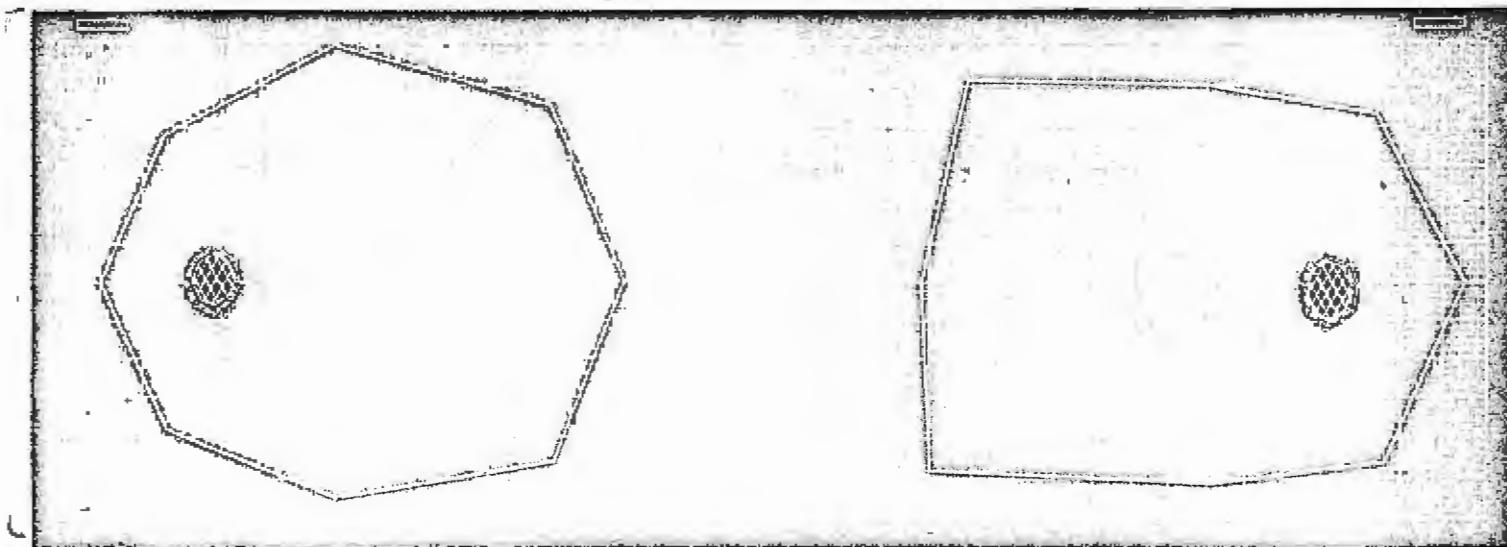


DATE: May 2, 1962

TIME: 2:00 P.M.

OBSERVATION: The right eye shows a highly irregular restriction of the white peripheral field. Both eyes show an enlargement of the physiological blind spot for the colors blue and red, and the right physiological blind spot shows an enlargement for white. The color blue was not recognized in the inferior or temporal fields for the left eye, and the color red was not recognized in the temporal field of the right eye, or in the superior field of the left eye.

VISUAL FIELDS 226 DAYS AFTER DENTAL THERAPY



DATE: December 14, 1962

TIME: 3:50 P.M.

OBSERVATION: The visual fields are found to be normal in both eyes.

PATIENT: Mrs. D. R., age 57.

DENTAL EXAMINATION:

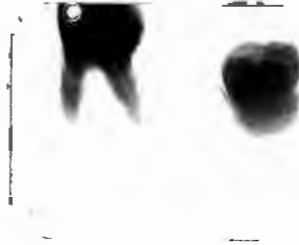
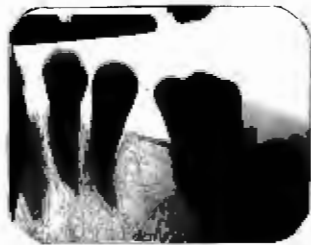CHIEF COMPLAINT: No subjective complaints.

DIAGNOSIS: Upper right unerupted, impacted 3rd molar which was impacted against the roots of the 2nd molar. This pressure has caused a destruction of a portion of the roots of the 2nd molar.

Lower left 1st molar root fragment, and apparent surrounding residual infection.

Lower left unerupted 3rd molar with indications of pericoronal infection. (Infection of the developmental membrane).

EXTENT OF INVOLVEMENT: Pathology is indicated in all areas mentioned above.



ESTIMATED DURATION OF INFECTION: Impacted teeth have been present for many years. The root fragment and residual infection has probably been present for several years also.

OPTOMETRIC EXAMINATION:


VISION: R. E. 20/15 L. E. 20/40 Through habitual prescription.

OPHTHALMOSCOPY: Both eyes were found to be normal.

CHIEF COMPLAINT: Frontal headache in the afternoons.

VISUAL FIELDS: As shown below.

VISUAL FIELDS BEFORE DENTAL THERAPY

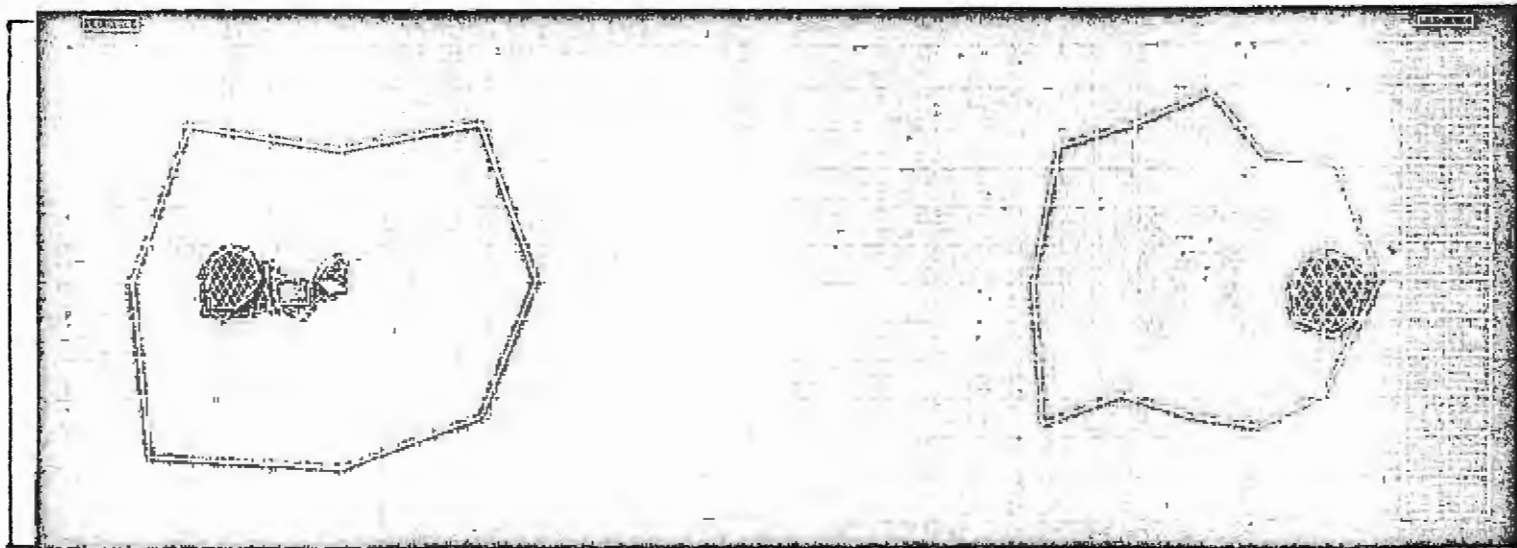


DATE: April 2, 1962

TIME: 10:00 A.M.

OBSERVATION: There is an enlargement of the physiological blind spot of both eyes for the colors red and blue. Absolute, red, and blue para-central scotomas are present in the left eye. No peripheral fields were taken.

VISUAL FIELDS 32 DAYS AFTER DENTAL THERAPY



DATE: May 4, 1962

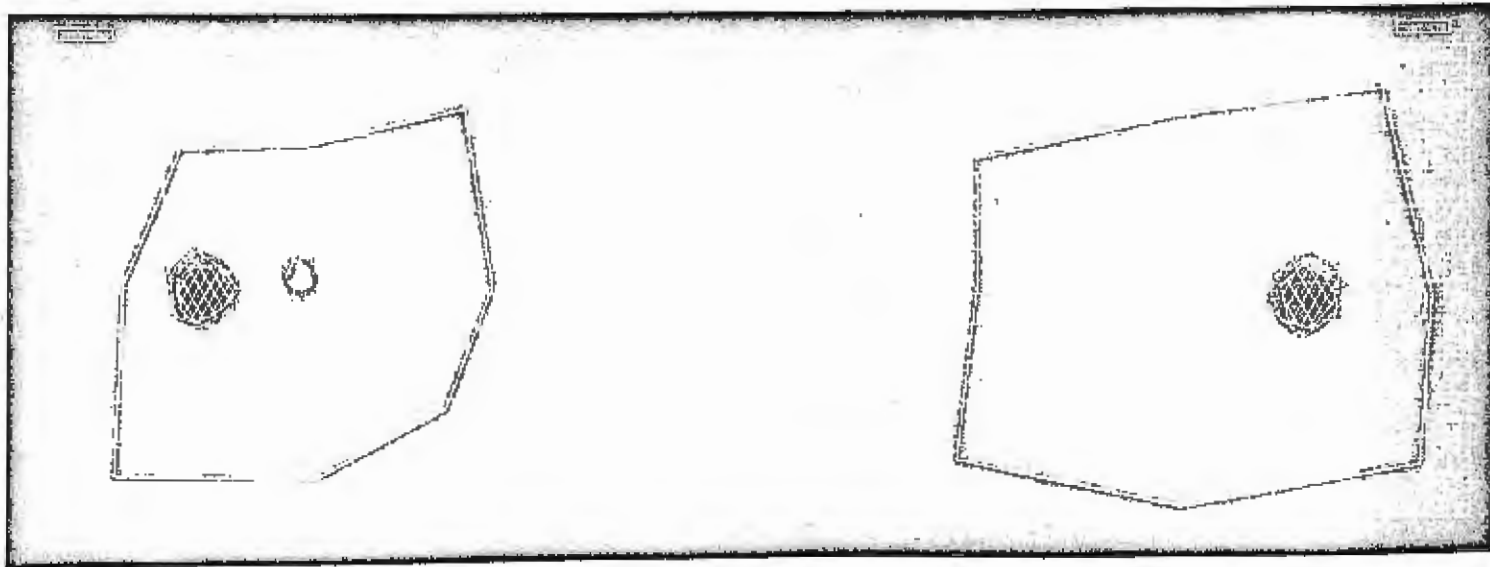
TIME: 8:30 A.M.

OBSERVATION: Both eyes show an irregular peripheral field.

OBSERVATION (Cont.): The left eye shows a slight enlargement of the physiological blind spot for the colors red and blue, and a paracentral scotoma for white, red and blue. The absolute paracentral scotoma has decreased slightly in size.

The right eye shows an enlarged physiological blind spot for white, and for the colors red and blue.

VISUAL FIELDS 116 DAYS AFTER DENTAL THERAPY



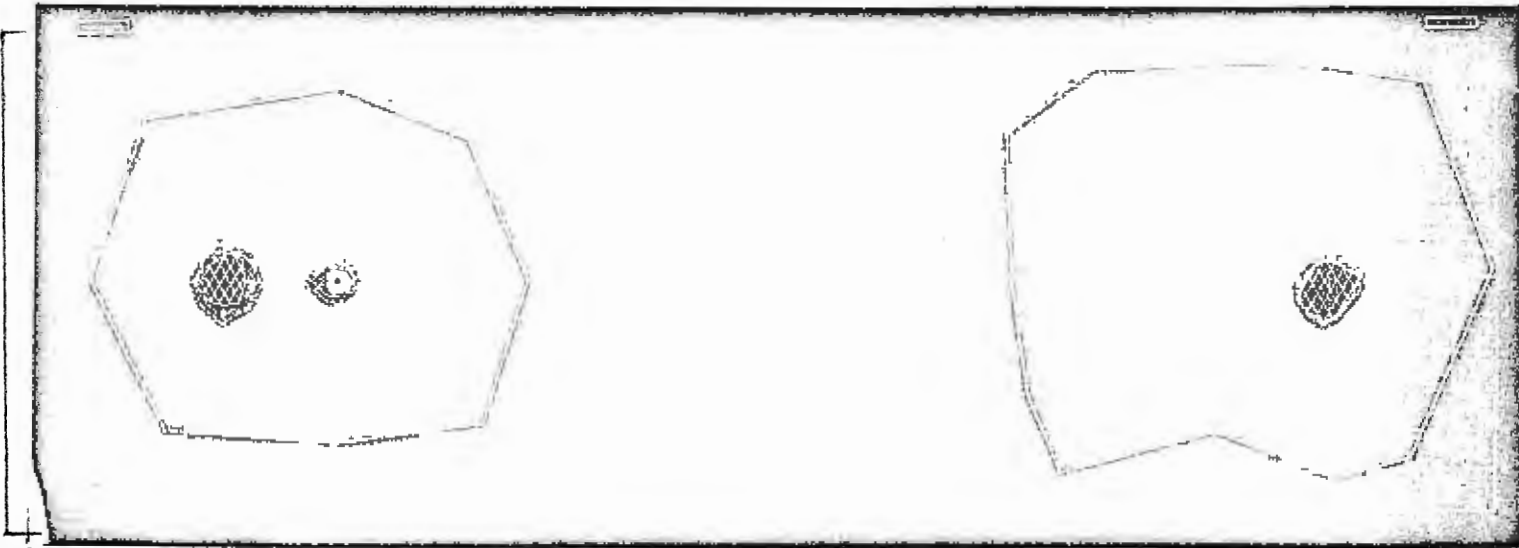
DATE: July 27, 1962

TIME: 10:30 A.M.

OBSERVATION: Both eyes show an enlarged physiological blind spot for the colors red and blue.

The left eye shows an irregular restriction of the peripheral field, and a paracentral scotoma for white, red, and blue. The absolute scotoma shows a slight enlargement.

VISUAL FIELDS 241 DAYS AFTER DENTAL THERAPY



DATE: November 29, 1962

TIME: 10:30 A.M.

OBSERVATION: The left eye has retained a contracted peripheral field, an absolute pericentral scotoma, and a central scotoma for the colors red and blue. The physiological blind spot also shows an enlargement for the colors.

The right eye is approaching normal.

CONCLUSION

Early in this research program, a patient with normal color fields was referred for full mouth x-rays on the basis of symmetrically enlarged physiological blind spots for white. The x-rays, and physical examination were found to be negative.

It was then felt that irregularities of diagnostic significance would include: restricted peripheral form fields, enlargement of the physiological blind spot for white in conjunction with the colors, all absolute scotomas, and the paracentral scotomas for red and blue. It was subsequently found that color scotomas appearing at about 12 degrees from the fixation point; in the superior nasal and superior temporal sectors of the field of vision, are of minimal diagnostic value, in that these areas seem to be subject to doubt even by persons known to be free from oral pathology. However, all other paracentral scotomas for the colors red and blue are considered to be indicative of focal infection.

It would appear that a focal infection is equally capable of representation in either or both eyes, and that there is no correlation between the location of the oral pathology and the side of the ocular affection. It is further suggested that the chronic, as opposed to the acute infection, is more likely to be represented in the eye, and as in the case of D. R., if left untreated may pose a threat to the patients sight.

It is felt that this research program has precipitated data supporting the contention that focal infections are manifest in the eye. It is therefore hoped that this presentation will stimulate the curiosity of the practitioner who is confronted with the perplexing problem of prescribing less and less effective lenses for the patient diagnosed to have a "non-treatable" macular degeneration; or for the patient who offers vague subjective symptoms as an excuse for not being able to wear his prescription with comfort.